

Stromal Demarcation Line in Pulsed Versus Continuous Light Accelerated Corneal Cross-linking for Keratoconus

Alireza Peyman, MD; Alireza Nouralishahi, MD; Farhad Hafezi, MD, PhD; Sabine Kling, PhD; Mohamadreza Peyman, MD

ABSTRACT

PURPOSE: To compare the stromal demarcation line depth in pulsed versus continuous corneal cross-linking (CXL) for keratoconus.

METHODS: Seventy eyes underwent epithelium-off cross-linking, with 0.1% riboflavin applied during 10 minutes prior to ultraviolet irradiation at 30 mW/cm². Thirty-six eyes received pulsed irradiation (1 second on, 1 second off) for 8 minutes and 34 eyes underwent continuous irradiation for 4 minutes. Total fluence was 7.2 J/cm² for both groups. Patients were evaluated at 3 months after the procedure.

RESULTS: A significantly deeper stromal demarcation line was observed in the pulsed group compared to the continuous group (201.11 ± 27.76 vs 159.88 ± 20.86 μm; *P* < .001).

CONCLUSIONS: The pulsed corneal cross-linking protocol induced a significantly deeper stromal demarcation line when compared to the 4 minutes of highly accelerated continuous CXL protocol. Neither CXL protocol induced a shallower demarcation line comparable to less accelerated CXL protocols previously reported.

[*J Refract Surg.* 2016;32(3):206-208.]

The biomechanical characteristics of the cornea are governed by the collagen scaffold, the collagen compound, and inter-fibrillar and intra-fibrillar bonding between collagen and proteoglycans. The purpose of corneal cross-linking (CXL) with riboflavin and ultraviolet-A is to induce additional cross-links in the extracellular matrix and to increase the mechanical resistance.¹

Conventional CXL with a continuous irradiation of 3 mW/cm² during 30 minutes is considered safe and effective in the prevention of keratoconus progression and secondary ectasias²⁻⁴; yet, the procedure is time-consuming. According to the Bunsen–Roscoe law of reciprocity, theoretically, a setting with higher ultraviolet energy and shorter irradiation times should have the same photobiological effect, as long as the total energy dose remains the same. Accelerated techniques emerged, aiming to shorten the time of the procedure by delivering higher power in a shorter time.⁵ However, a lower experimental and clinical efficacy of accelerated CXL has been reported, which was attributed to the higher consumption and shortage of oxygen in the stroma.^{4,6}

Delivering ultraviolet light with an on-off pattern is expected to allow more oxygen to diffuse into the corneal stroma, lead to an enhanced release of singlet oxygen, and allow a more effective cross-linking of the collagen molecules. However, Kamaev et al. demonstrated that the time for oxygen replenishment in the stroma is much longer (several minutes) than the pulsed ultraviolet settings currently

From the Isfahan University of Medical Sciences, Isfahan, Iran (AP, AN); the ELZA Institute, Zurich, Switzerland (FH); the Department of Ophthalmology, University of Southern California–Los Angeles, Los Angeles, California (FH); the Center for Applied Biotechnology and Molecular Medicine, University of Zurich, Zurich, Switzerland (FH, SK); and the Department of Ophthalmology, University of Malaya, Kuala Lumpur, Malaysia (MP).

Submitted: November 6, 2015; Accepted: January 15, 2016

Dr. Hafezi is the chief scientific and medical officer of EMAGine AG (Zug, Switzerland) and co-inventor of the PCT/CH2012/000090 application regarding CXL technology. The remaining authors have no financial or proprietary interest in the materials presented herein.

Correspondence: Alireza Peyman, MD, Feiz Hospital, Modares St., Isfahan, Iran. E-mail: drpeyman@hotmail.com

doi:10.3928/1081597X-20160204-03

used in clinics (with pauses of one second for oxygen replenishment).⁷

We analyzed accelerated CXL protocols with continuous and pulsed ultraviolet irradiation in a series of 70 patients with progressive keratoconus. We performed a clinical follow-up at 3 months after the procedure and determined the depth of the treated corneal tissue by identifying the demarcation line using anterior segment optical coherence tomography (OCT).

PATIENTS AND METHODS

In this prospective interventional study, 70 eyes of 70 patients were enrolled. The study protocol was approved by the institutional review board of the Isfahan University of Medical Sciences and was in agreement with the tenets of the Declaration of Helsinki. The riboflavin solution used was iso-osmotic dextran-free riboflavin 0.1% (VibeX Rapid; Avedro, Inc., Waltham, MA), which was instilled every 2 minutes for 10 minutes after total removal of epithelium in the central 9 mm. Patients were randomized to either pulsed or continuous irradiation groups: 36 eyes of 36 patients underwent pulsed light accelerated CXL and 34 eyes of 34 patients underwent continuous light accelerated CXL. We used the KXL I ultraviolet-A device (Avedro, Inc.) for irradiation. In the pulsed group, the setting was 1 second on/1 second off ultraviolet-A exposure at 30 mW/cm² for 8 minutes, corresponding to a fluence of 7.2 J/cm². In the continuous group, the ultraviolet-A power was set to 30 mW/cm² and 4 minutes of continuous ultraviolet-A light exposure, also resulting in a fluence of 7.2 J/cm².

We included patients who met at least three of the following four criteria for progressive keratoconus during the year before enrollment in the study: (1) a worsening of the corrected distance visual acuity of more than two Snellen lines; (2) an increase of sphere or astigmatism greater than 0.75 diopter; (3) an increase of maximum keratometry readings of more than 1.00 diopter; and (4) a reduction of the thinnest point of corneal thickness of more than 10 μ m, as measured by ultrasound pachymetry.

Patients were evaluated preoperatively and at 3 months after the procedure regarding their uncorrected and corrected distance visual acuity and refractive error. Corneal Scheimpflug tomography by Pentacam (Oculus Optikgeräte GmbH, Wetzlar, Germany) and OCT of the cornea with Spectralis HRA (Heidelberg Engineering, Heidelberg, Germany) were performed to evaluate the cornea. For each eye, the depth of demarcation line was determined and reported as the mean of four measurement points (at 1- and 2-mm central rings intercept with the horizontal line in cornea OCT). The

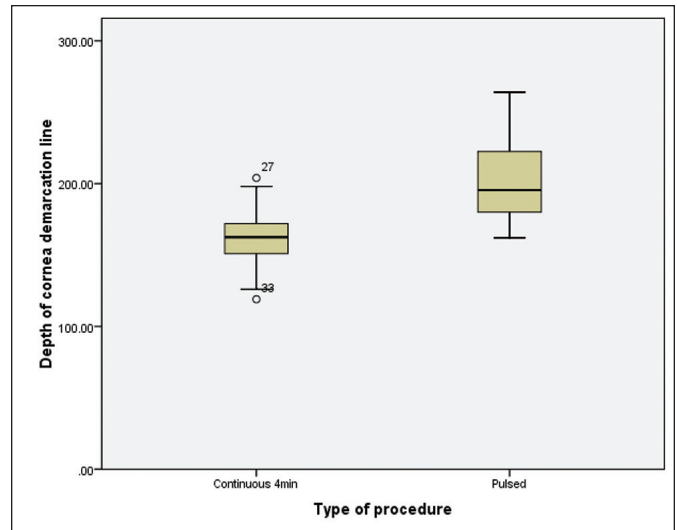


Figure 1. Depth of cornea demarcation line in microns in the pulsed and continuous groups.

evaluators were masked with regard to study groups. Statistical analyses were done using SPSS for Windows software (version 16.0; SPSS, Inc., Chicago, IL).

RESULTS

Thirty-six eyes of 36 patients were included in the pulsed group and 34 eyes of 34 patients in the continuous group.

The depth of cornea demarcation line on anterior segment OCT was $201.11 \pm 27.76 \mu$ m in the pulsed group and $159.88 \pm 20.86 \mu$ m in the continuous group. The difference was statistically significant ($P < .001$, independent sample *t* test) (Figure 1).

None of the patients in either group had any complication attributable to the procedure.

DISCUSSION

In this study, we compared two accelerated CXL protocols using continuous light and pulsed light. We observed a depth of the stromal demarcation after pulsed CXL similar to that reported by Mazzotta et al.⁸ (8 minutes pulsed versus 4 minutes at 30 mW/cm²). An on-off pattern of ultraviolet light might be expected to let more oxygen diffuse into the corneal stroma, enhance release of singlet oxygen, and allow a more effective CXL. However, when compared to the standard Dresden protocol with a demarcation line of 300 to 350 μ m, and even when compared to the depth of the demarcation line using 9 mW/cm² for 10 minutes (demarcation line depth 288 μ m),⁹ both protocols tested here led to a more shallow demarcation line, suggesting less cross-linking effect.

Although we were not able to find any significant differences between pulsed and continuous accelerat-

ed CXL protocols regarding vision, refraction, and cornea topographic characteristics during the 3 months of follow-up (data not shown), the stromal demarcation line after pulsed accelerated CXL was significantly deeper ($\Delta = 41.23 \mu\text{m}$) than after continuous highly accelerated CXL.

The stromal demarcation line is considered a clinical evaluation parameter for the depth of effective cross-linking and hence in our comparison pulsed CXL had a superior effect compared to continuous CXL. However, according to Fick's law of diffusion, there is not enough time for substantial oxygen diffusion during the 1-second ultraviolet-off period and hence this fact cannot explain the increased CXL efficacy. Another parameter that needs to be considered is the pulsed CXL protocol required an overall ultraviolet irradiation time of 8 minutes, whereas the continuous protocol required only 4 minutes. Although oxygen is immediately consumed, there is a higher net oxygen flux during longer ultraviolet irradiations, independently of whether pulsed or continuous ultraviolet light is applied.¹⁰ Further testing, such as with an irradiation of $15 \text{ mW}/\text{cm}^2$ during 8 minutes, will help to clarify the importance of overall irradiation duration and pulsed ultraviolet administration.

Although not experimentally proven yet, many believe that the depth of the demarcation line is a clinical parameter indicating the depth of effective CXL treatment. The pulsed irradiation protocol currently proposed for clinical use requires a total irradiation time of 8 minutes using $30 \text{ mW}/\text{cm}^2$ in an on-off pattern. It provides a demarcation line depth of approximately $200 \mu\text{m}$. In comparison, the currently widely used 10-minute continuous light irradiation protocol with $9 \text{ mW}/\text{cm}^2$ takes only 2 minutes longer, but adds almost $90 \mu\text{m}$ to the demarcation line depth.

AUTHOR CONTRIBUTIONS

Study concept and design (AP, MP); data collection (AP, AN); analysis and interpretation of data (AP, AN, FH, SK, MP); writing the manuscript (AP, AN); critical revision of the manuscript (FH, SK, MP); statistical expertise (AP, AN, MP); supervision (MP)

REFERENCES

1. Raiskup F, Spoerl E. Corneal crosslinking with riboflavin and ultraviolet A: I. Principles. *Ocul Surf*. 2013;11:65-74.
2. Randleman JB, Khandelwal SS, Hafezi F. Corneal cross-linking. *Surv Ophthalmol*. 2015;60:509-523.
3. Razmjoo H, Rahimi B, Kharraji M, Koosha N, Peyman A. Corneal haze and visual outcome after collagen crosslinking for keratoconus: a comparison between total epithelium off and partial epithelial removal methods. *Adv Biomed Res*. 2014;3:221.
4. Richoz O, Hammer A, Tabibian D, Gatziofias Z, Hafezi F. The biomechanical effect of corneal collagen cross-linking (CXL) with riboflavin and UV-A is oxygen dependent. *Translational Vision Science & Technology*. 2013;2:6.
5. Tomita M, Mita M, Huseynova T. Accelerated versus conventional corneal collagen crosslinking. *J Cataract Refract Surg*. 2014;40:1013-1020.
6. Hammer A, Richoz O, Arba Mosquera S, Tabibian D, Hoogewoud F, Hafezi F. Corneal biomechanical properties at different corneal cross-linking (CXL) irradiances. *Invest Ophthalmol Vis Sci*. 2014;55:2881-2884.
7. Kamaev P, Friedman MD, Sherr E, Muller D. Photochemical kinetics of corneal cross-linking with riboflavin. *Invest Ophthalmol Vis Sci*. 2012;53:2360-2367.
8. Mazzotta C, Traversi C, Caragiuli S, Rechichi M. Pulsed vs continuous light accelerated corneal collagen crosslinking: in vivo qualitative investigation by confocal microscopy and corneal OCT. *Eye (Lond)*. 2014;28:1179-1183.
9. Kymionis GD, Tsoulnaras KI, Grentzelos MA, et al. Corneal stroma demarcation line after standard and high-intensity collagen crosslinking determined with anterior segment optical coherence tomography. *J Cataract Refract Surg*. 2014;40:736-740.
10. Hammer A, Kling S, Boldi MO, et al. Establishing corneal cross-linking with riboflavin and UV-A in the mouse cornea in vivo: biomechanical analysis. *Invest Ophthalmol Vis Sci*. 2015;56:6581-6590.